

TERUMO PENPOL REVIEW

ON BLOOD MANAGEMENT SYSTEMS

JAN-MAR **16** NUMBER **85**

Copyright :

© 2015 Baldane S, et al. This is an open-access article distributed under the terms of the Creative Commons Attribution License, which permits unrestricted use, distribution, and reproduction in any medium, provided the original author and source are credited.

J Gen Practice 2015, S1:1

For Private Circulation For Educational Purpose Only

Published in every quarter by TERUMO PENPOL Private Limited

TERUMO PENPOL®

Plasmapheresis should be Considered in Addition to Standard Therapy in Patients with Familial Chylomicronemia Syndrome

Suleyman Baldane^{1,*}, Banu Bozkurt² and Levent Kebapcilar¹

¹Department of Internal Medicine, Division of Endocrinology and Metabolism, Faculty of Medicine, Selcuk University, Konya, Turkey

²Department of Ophthalmology, Faculty of Medicine, Selcuk University, Konya, Turkey

*Corresponding author: Suleyman Baldane MD, Department of Internal Medicine, Selcuk University, Konya, Postal code: 42075, Turkey, Tel: +903322244685; Fax: +903322412184; E-mail: baldane42@hotmail.com

Received date: May 19, 2015 Accepted date: June 15, 2015, Published date: June 18, 2015

Clinical Image

Keywords: Severe hypertriglyceridemia; Familial chylomicronemia; Plasmapheresis

A 52-year-old man was referred to our clinic for management of severe hypertriglyceridemia diagnosed five years

previously as a result of routine blood work. His medical history was also significant for type 2 diabetes mellitus. His hypertriglyceridemia had been poorly controlled, because of medication noncompliance. He did not use any medication for his severe hypertriglyceridemia

since one year. The patient did not smoke or consume alcohol. He was asymptomatic and had no history of abdominal pain or pancreatitis. There was no evidence of abdominal distension, rebound tenderness or guarding. There was only family history of dyslipidemia. The patient's father and brother both were diagnosed with hyperlipidemia.

At the time of admission, the patient's body weight was 85 kg and height was 1.72 m (body mass index was 28.8 kg/m²) with a waist circumference of 96 cm. His

blood pressure was 130/70 mmHg. No other abnormalities were noted on physical examination. During sampling, his blood was found to be highly viscous and when blood was drawn, it was noted to be milky (Figure 1).

Initial laboratory investigations were fasting serum total cholesterol 1126 mg/dl (Normal Range (NR): 130-200), HDL cholesterol 21 mg/dl (NR: 40-60), triglycerides 5452 mg/dl (NR: 40-200) and direct LDL cholesterol 277 mg/dl (NR: 50-100). Fasting glucose was 337 mg/dl (NR: 70-100) and

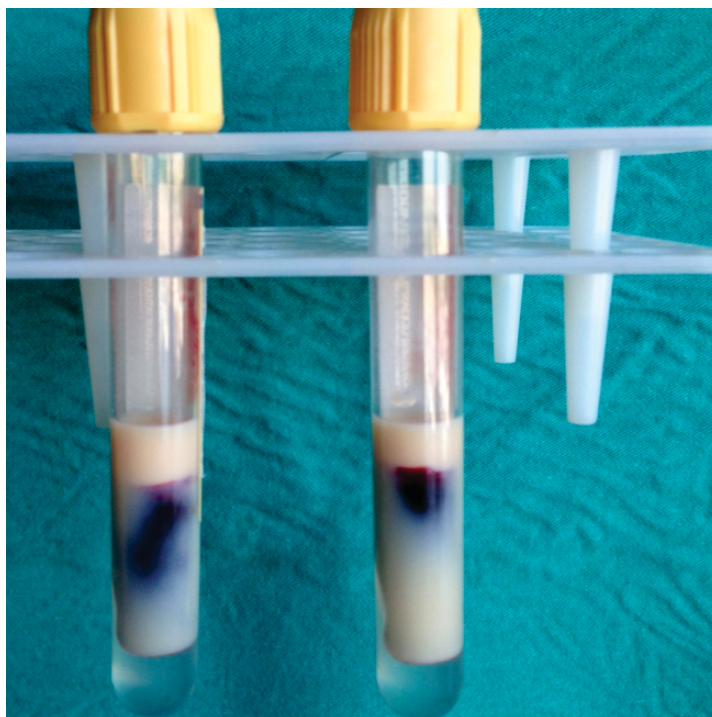


Figure 1: Milky appearance of drawn blood.

glycosylated hemoglobin 13.6% (NR: 4-6). Thyroid stimulating hormone, liver transaminase, amylase, lipase, blood urea nitrogen and creatinine levels were all normal, and urine protein test was negative. Ophthalmological examination revealed lipemia retinalis. Due to extremely high triglyceride levels, the appearance of a milky white retinal arteries and veins, along with a salmon-colored retinal background a diagnosis of lipemia retinalis was made (Figure 2).

five days the patient was asymptomatic and his triglyceride level had much more increased to 8912 mg/dl. Accordingly, the decision was made to initiate plasmapheresis to acutely lower the serum TG level. No complications developed during or after the procedures. After six days, triglyceride levels were modestly improved at 4726 mg/dl, and 10 days later his triglyceride was 1226 mg/dl. The plasmapheresis treatment was ceased after two sessions.

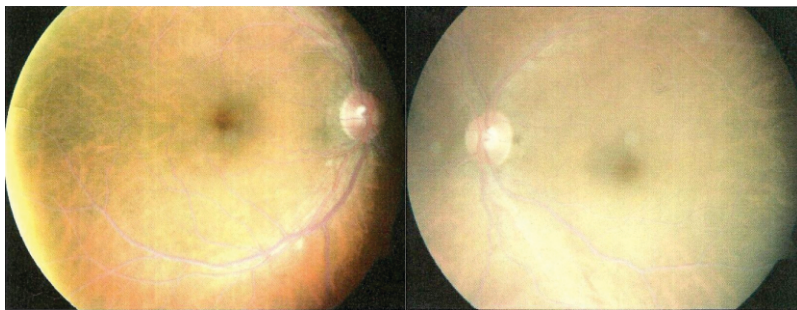


Figure 2: The appearance of milky white retinal vasculature is pathognomonic for lipemia retinalis.

Patients with severe primary hypertriglyceridemia (type V hyperlipoproteinemia; Mixed hypertriglyceridemia; Fredrickson's classification) was diagnosed. We started fat-restricted diet, fibrate, fish oil, insulin dextrose infusion and subcutaneous heparin treatment. Within

Fasting chylomicronemia (type V hyperlipoproteinemia; Mixed hypertriglyceridemia; Fredrickson's classification) is characterized by triglyceride levels above the 99th percentile in association with a creamy plasma supernatant and cloudy infranatant due to increases

infranatant due to increases in chylomicrons and VLDL. Patients with severe hypertriglyceridemia (>1000 mg/dL) may develop chylomicronemia syndrome. These patients may manifest short-term memory loss, abdominal pain and/or pancreatitis, eruptive xanthoma and lipemia retinalis. Majority of the patients have secondary form including some other dyslipidemia types (e.g. familial hypertriglyceridemia due to partial lipoprotein lipase (LPL) deficiency) that are exacerbated by some factors such as poor controlled diabetes or utilization of drugs that elevate triglyceride levels. In addition there is primary form of type V hyperlipoproteinemia, in which there is not a deficiency of LPL, nor its ligand apo CII. The actual cause of this disorder is not clearly known; however, apo E4, which acts as a ligand for hepatic chylomicron and VLDL remnant receptors, may play role in this disorder.

Fasting chylomicronemia can be diagnosed by confirming the presence of chylomicrons and excess VLDL on agarose gel electrophoresis or ultracentrifugal analysis. A simple technique is to

refrigerate plasma overnight and examine the specimen for a creamy supernatant from chylomicrons and a turbid VLDL-rich infranatant.

The initial treatment for severe hypertriglyceridemia should be lifestyle therapy; a combination of diet modification and drug therapy may also be considered. Standard therapeutic measures are based on the use of lipid-lowering agents (fenofibrate, gemfibrozil, niacin, W-3 fatty acids), and insulin in diabetic patients. In patients with severe hypertriglyceridemia, a fibrate should be used as a first-line agent. Other treatment options include insulin and heparin. Insulin can decrease triglyceride levels by increasing LPL activity, whereas heparin can do it by increasing release of endothelial LPL.

However, when standard medical therapies have failed, nonpharmacological approaches based upon the removal of triglycerides with therapeutic plasmapheresis can also provide benefit to patients, with severe hypertriglyceridemia to reduce triglycerides. Plasmapheresis is the fastest way of decreasing

triglyceride levels. There is not a current guideline that recommends initiation time of plasmapheresis, its frequency and target triglyceride levels; however, plasmapheresis has been shown to be clearly beneficial in patients with hypertriglyceridemic pancreatitis. Plasmapheresis treatment should be planned individually depending on patient's clinical status. Since plasmapheresis remains the quickest method to reduce the triglyceride levels, early initiation results in improved tissue perfusion and can prevent end-organ complications. Therefore, in patients with severe hypertriglyceridemia such as familial chylomicronemia, plasmapheresis should be considered in addition to standard therapy.

REGISTERED OFFICE

Terumo Penpol Private Limited
P.B.No. 6105, I-2 , Jawahar Nagar,
Thiruvananthapuram - 695003, Kerala, India.
Ph.No : 0471-3015500 / 501
Fax : 0471-2721519
CIN : U33112KL1985PTC004531

www.terumopenpol.com
www.terumobct.com

Toll Free No. 1800 3000 7070

CENTRAL SALES OFFICE

New No.71, Gandhi Court,
4th Main Road, Gandhi Nagar,
Adayar, Chennai - 600020
Tel: 044-42054538, 044-30957200 /01 / 02 / 03 / 04 / 05
tplmarketing@terumopenpol.com

MARKETING OFFICE

YGRA-12, TC 4/1399(3),
Kuravankonam,
Kowdiar Post,
Thiruvananthapuram-695003
pmt@terumopenpol.com

ZONAL OFFICE

DELHI

3E/9, Second Floor,
Jhandewalan Etn, Delhi
Tel : 011-46921062

KOLKATA

839/1, Lake Town, Block A
Kolkatta -700089
West Bengal
Tel : 033-25344609

MUMBAI

Divya Jyot CHS Ltd.,
B-7, Ground floor,
R. K. Singh Marg, Old Nagardas Road,
Andheri (East), Mumbai – 400 069
Tel : 022-2824 0304 / 09320231762

TERUMO PENPOL®