

TERUMO PENPOL REVIEW

ON BLOOD MANAGEMENT SYSTEMS

OCT-DEC **16** NUMBER **88**

Copyright :

© 2016 Massa Zantah et al.
This is an open access article distributed under the Creative Commons Attribution License, which permits unrestricted use, distribution, and reproduction in any medium, provided the original work is properly cited.

Case Reports in Pulmonology
Volume 2016, Article ID
1287690, 3 pages
<http://dx.doi.org/10.1155/2016/1287690>

For Private Circulation For
Educational Purpose Only

Published in every quarter by
TERUMO PENPOL Private
Limited

TERUMO PENPOL®

Acute Respiratory Failure due to Neuromyelitis Optica Treated Successfully with Plasmapheresis

Massa Zantah,¹ Timothy B. Coyle,² and Debapriya Datta²

¹Department of Medicine, University of CT Health Center, Farmington, CT 06030, USA

²Division of Pulmonary & Critical Care Medicine, University of CT Health Center, Farmington, CT 06030, USA

1. Introduction

Neuromyelitis Optica (NMO) is a severe demyelinating autoimmune disease involving the central nervous system. Acute respiratory failure (ARF) due to monophasic NMO is uncommon. We report a case of NMO who developed ARF related to cervical myelitis, which was refractory to pulse dose steroid therapy, but resolved with plasmapheresis.

2. Case Report

A 53-year-old female with a history of NMO with positive NMO-immunoglobulin G (NMO-IgG)/aquaporin-4 antibodies (AQP4-Ab) presented to the emergency department (ED) with complaints of headache, left sided weakness, numbness, and tingling for 3 days. Her medications included prednisone 5mg daily, escitalopram, amitriptyline, and azathioprine. The

patient denied smoking, alcohol, or illicit drug use.

In the ED, she was in mild respiratory distress with oxygen (O₂) saturation of 85% on room air. Other vital signs were normal. Lung and cardiovascular examination was normal. Neurological examination revealed mild weakness, decreased sensation to light touch, hyperreflexia, and a positive Babinski sign on the left. Laboratory data were normal. ABG revealed a pH of 7.46, pCO₂ of 37.1, and pO₂ of 60.6 on O₂ at 2 liters/minute by nasal cannula. Chest X-ray (Figure 1) showed hypoinflated lung fields with bibasal atelectasis and elevated hemidiaphragms. The patient was started on O₂ and intravenous pulse dose steroids and continued on her azathioprine home dose. Over the next few hours, the patient became increasingly dyspneic and hypoxic. Negative inspiratory force was -20 cm H₂O. A computed tomogram (CT) scan of the chest (Figure 2) showed bibasilar atelectasis. Lung ultrasound revealed impaired movement of the

left diaphragm, consistent with paresis. The patient was started on bilevel positive airway pressure (BIPAP). Cervical spine MRI (Figure 3) showed increased T2 signal within the spinal cord with heterogeneous enhancement in the cord extending between the mid-C2 and T1 vertebrae.

The patient's ARF was felt to be due to cervical cord involvement by NMO, resulting in diaphragmatic weakness. Patient was started on pulsed steroids: methylprednisolone at 1 gram IV daily for 3 days, followed by 1.5 gm/kg/day for 3 days, following which it was rapidly tapered off. Plasmapheresis was started on day 4 after no significant clinical response was seen after 3 days of pulsed steroid therapy. Plasmapheresis was performed daily for 5 days, following which the patient's respiratory distress and oxygenation improved and BIPAP was discontinued. Her diaphragmatic excursion normalized on fluoroscopy. Her neurologic symptoms also improved significantly.

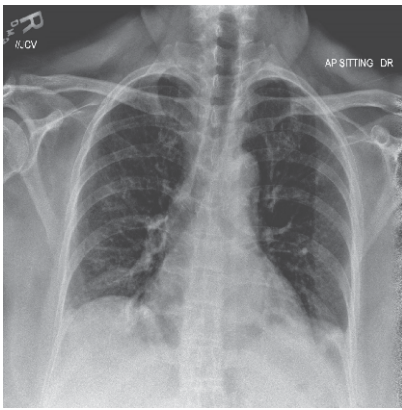


Figure 1: Chest X-ray showing hypoinflated lung fields, with basal atelectasis and elevated hemidiaphragms.

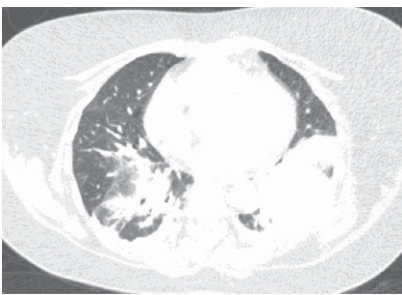


Figure 2: CT chest showing bibasal atelectasis, more prominent on the left.

3. Discussion

NMO, also known as Devic's disease, is a rare but severe inflammatory, demyelinating, and necrotizing autoimmune disease of the central nervous system which is distinct from multiple sclerosis (MS) [1]. It is characterized by recurrent attacks of optic neuritis, myelitis, and presence of NMO-immunoglobulin G (NMO-IgG)/aquaporin-4 antibodies (AQP4-Ab) [1]. The clinical manifestations of NMO are more severe than

those of "typical" MS [1, 2]. ARF is unknown in MS. Cerebrospinal fluid and MRI findings can distinguish NMO from MS [3].

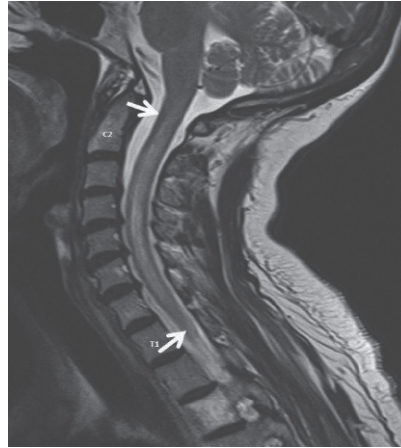

Figure 3: MRI of spine showing intramedullary demyelination in the spinal cord, evident as enhanced T2 signal, with peripheral contrast enhancement, extending from C2 to T1 vertebral body (arrows).

A revised set of criteria for diagnosis of NMO were proposed in 2006 [1]. These guidelines require two definite criteria: (i) optic neuritis and (ii) acute myelitis plus at least two of three supportive criteria: (i) contiguous spinal cord MRI lesion extending over 3 vertebral segments, (ii) brain MRI not meeting criteria for multiple sclerosis, and (iii) NMO-IgG seropositive status.

Spinal cord involvement in NMO usually presents as transverse myelitis with paraparesis or quadriparesis, a sensory

level and sphincter dysfunction [4, 5]. NMO may also present as radicular pain, paroxysmal tonic spasms, nausea, and intractable hiccups [4]. Due to involvement of the respiratory center in the medulla, neurogenic ARF and death can occur [2, 3].

In one series [6], respiratory dysfunction was reported in 22% patients after onset of NMO. In 16% of these patients, respiratory failure was related to a relapse; 7% required invasive mechanical ventilation. In another series [4], ARF caused by acute cervical myelitis occurred 19 times (33%) in 16 relapsing patients and was responsible for death in 15 (93%) of these patients. Only two patients with monophasic NMO (2%) had this complication, with both patients recovering [3].

The guidelines regarding management are based on expert opinions [2, 4]. In one series [4], corticosteroids resulted in improvement in 80% of patients. Plasmapheresis resulted in improvement in 2/3rd of steroid-refractory patients. Majority of patients with acute NMO respond within 1–5 days of high dose intravenous methylprednisolone 1 gram

daily for 3–5 consecutive days, followed by slow taper [2, 4]. Plasmapheresis and / or intravenous immunoglobulins are used in steroid-refractory cases [7]. Diaphragmatic pacing has also been reported to successfully wean patient with ARF due to NMO requiring mechanical ventilation [8].

In contrast to MS, maintenance therapy with immunosuppressives rather than immunomodulators achieves better prevention of recurrences [9]. Azathioprine, low dose prednisolone, or rituximab may be used for maintenance [10]. Methotrexate, cyclophosphamide, mycophenolate, and mitoxantrone have been used with variable success [4, 9].

The patient was subsequently started on rituximab. On subsequent outpatient follow-up, resolution of her neurologic symptoms was noted.

Conflict of Interests

The authors declare that there is no conflict of interests.

References

- [1] D. M. Wingerchuk, V. A. Lennon, S. J. Pittock, C. F. Lucchinetti, and B. G. Weinshenker, "Revised diagnostic criteria for neuromyelitis optica," *Neurology*, vol. 66, no. 10, pp. 1485–1489, 2006.
- [2] J. Sellner, M. Boggild, M. Clanet et al., "EFNS guidelines on diagnosis and management of neuromyelitis optica," *European Journal of Neurology*, vol. 17, no. 8, pp. 1019–1032, 2010.
- [3] W. Krampla, F. Aboul-Enein, J. Jecel et al., "Spinal cord lesions in patients with neuromyelitis optica: a retrospective long-term MRI follow-up study," *European Radiology*, vol. 19, no. 10, pp. 2535–2543, 2009.
- [4] D. M. Wingerchuk, W. F. Hogancamp, P. C. O'Brien, and B. G. Weinshenker, "The clinical course of neuromyelitis optica (Devic's syndrome)," *Neurology*, vol. 53, no. 5, pp. 1107–1114, 1999.
- [5] D. M. Wingerchuk and B. G. Weinshenker, "Neuromyelitis optica: clinical predictors of a relapsing course and survival," *Neurology*, vol. 60, no. 5, pp. 848–853, 2003.
- [6] L. Elson, Y. Y. Goh, R. Trafford, K. Mutch, and A. Jacob, "How often does respiratory failure occur in neuromyelitis optica?" *Journal of Neurology, Neurosurgery & Psychiatry*, vol. 84, article e2, 2013.
- [7] A. Mochizuki, A. Hayashi, S. Hisahara, and S. Shoji, "Steroidresponsive Devic's variant in Sjogren's syndrome," *Neurology*, vol. 54, no. 6, pp. 1391–1392, 2000.
- [8] M. R. Rahmlow, K. Boylan, and W. D. Freeman, "Diaphragmatic pacing to facilitate ventilator weaning in neuromyelitis optica-associated respiratory failure," *Multiple Sclerosis and Related Disorders*, vol. 1, no. 3, pp. 145–147, 2012.
- [9] C. Papeix, J.-S. Vidal, J. de Seze et al., "Immunosuppressive therapy is more effective than interferon in neuromyelitis optica," *Multiple Sclerosis*, vol. 13, no. 2, pp. 256–259, 2007.
- [10] A. Jacob, B. G. Weinshenker, I. Violich et al., "Treatment of neuromyelitis optica with rituximab: retrospective analysis of 25 patients," *Archives of Neurology*, vol. 65, no. 11, pp. 1443–1448, 2008.

REGISTERED OFFICE

Terumo Penpol Private Limited
P.B.No. 6105, I-2 , Jawahar Nagar,
Thiruvananthapuram - 695003, Kerala, India.
Ph.No : 0471-3015500 / 501
Fax : 0471-2721519
CIN : U33112KL1985PTC004531

www.terumopenpol.com
www.terumobct.com

Toll Free No. 1800 3000 7070

CENTRAL SALES OFFICE

No. 9, Padmanabha View
Gandhi Nagar 2nd Main Road.
Adayar, Chennai - 600 020.
Tel: 044-42054538, 044-30957200
tplmarketing@terumopenpol.com

MARKETING OFFICE

YGRA-12, TC 4/1399(3),
Kuravankonam,
Kowdiar Post,
Thiruvananthapuram-695003
Tel : 0471-3015647/49
pmt@terumopenpol.com

ZONAL OFFICE

DELHI

3E/9, Second Floor,
Jhandewalan Etn, Delhi
Tel : 011-46921062

KOLKATA

839/1, Lake Town, Block A
Kolkatta -700089
West Bengal
Tel : 033-25344609

MUMBAI

Divya Jyot CHS Ltd.,
B-7, Ground floor,
R. K. Singh Marg, Old Nagardas Road,
Andheri (East), Mumbai – 400 069
Tel : 022-2824 0304 / 09320231762

TERUMO PENPOL®